

**CASE REPORT: TODDLER'S FRACTURE OF THE FIBULA**

S. Butt<sup>1,3,4</sup>, S. I. Mahmood<sup>1,3,4</sup>, A. Saifuddin<sup>1,3,4</sup>, T. WR. Briggs<sup>2,3,4</sup>,  
W. Mustafa<sup>3,4</sup>.

**T**oddler's fracture usually refers to an occult non-displaced fracture of the distal tibia, which occurs when a child falls while learning to walk. Similar fractures have been described in other bones like fibula, femur, calcaneus and cuboid. We present a case of an isolated toddler's fracture of the fibula, which was very difficult to demonstrate on conventional radiographs and was only diagnosed following MRI and CT examination performed as part of a tumour staging workup. To our knowledge, this is the first MR description of a fibular toddler's fracture.

Keywords: toddler's fracture, fibula, conventional radiography, CT, MRI.

**КЛИНИЧЕСКОЕ НАБЛЮДЕНИЕ: ПЕРЕЛОМ МАЛОБЕРЦОВОЙ КОСТИ У РЕБЕНКА, НАЧИНАЮЩЕГО ХОДИТЬ**

С. Батт<sup>1,3,4</sup>, И. Махмуд<sup>1,3,4</sup>, А. Саифуддин<sup>1,3,4</sup>, Тим Бриггс<sup>2,3,4</sup>,  
В. Мустафа<sup>3,4</sup>.

**П**ереломы у детей, которые учатся ходить, обычно относятся к закрытым переломам дистального отдела большеберцовой кости без смещения. Подобные переломы были описаны в таких костях, как малоберцовая, бедренная, пяточная и кубовидная. Нами представлен случай изолированного перелома малоберцовой кости, визуализация которого при рентгенологическом исследовании была затруднена. Данный перелом был диагностирован только при проведении МРТ и КТ как части исследования по поиску онкологического процесса. Насколько нам известно, это первое описание перелома малоберцовой кости у детей, выявленного при помощи МРТ.

Ключевые слова: перелом малоберцовой кости, рентгенография, КТ, МРТ.

1 - The Royal National Orthopaedic Hospital NHS Trust. The Departments of Radiology and  
2 - Orthopaedic Oncology Stanmore, UK  
3 - The London Bone and Soft Tissue Tumour Service. London, UK  
4 - The Institute of Orthopaedics and Musculoskeletal Sciences. University College London, UK

1- Королевский национальный госпиталь ортопедии. Кафедра лучевой диагностики.  
2. Королевский национальный госпиталь ортопедии. Кафедра ортопедической онкологии  
Станмор, Великобритания  
3 - Отделение опухолей костей и мягких тканей. Лондон, Великобритания,  
4 - Институт ортопедии и мышечно-скелетной науки.  
Лондон, Великобритания.

**T**he term "toddler's fracture" was coined by Dunbar et al [1] to describe an occult non-displaced spiral fracture of the distal tibial shaft in children between 9 months and 3 years of age. The classical presentation is acute trivial trauma resulting in inability to bear weight on the affected side, point tenderness, warmth over the tibia and painful ankle dorsiflexion. On clinical examination, it is often not obvious that the problem is within the tibia, and radiographic examination of one or both extremities may have to be performed to identify the site of abnormality [2].

Toddler's fractures have also been described in other bones such as the calcaneum [3-5] and cuboid [6-7]. Isolated toddler's fracture of the fibula has also been described on plain radiographs and on nuclear medicine studies [8-10].

We present a case of toddler's fracture of the fibula, diagnosed by MRI and CT. The studies

were performed as part of a tumour staging workup, prompted by the plain radiographic findings and patient's clinical presentation. MR features of this not uncommon entity have not been described and should be known in order to make the correct diagnosis.

**Case Report.**

An 18-month-old male child presented to a District General Hospital with a 2-3 week history of sudden onset limp in the left leg. The child also complained of pain localised to the upper leg, although there was no history of trauma.

On examination, the child was systemically well and afebrile. There was mild tenderness over the left fibula, but no erythema, swelling or overt signs of infection. Haematological examination revealed a slightly raised white cell count, but normal ESR and CRP.

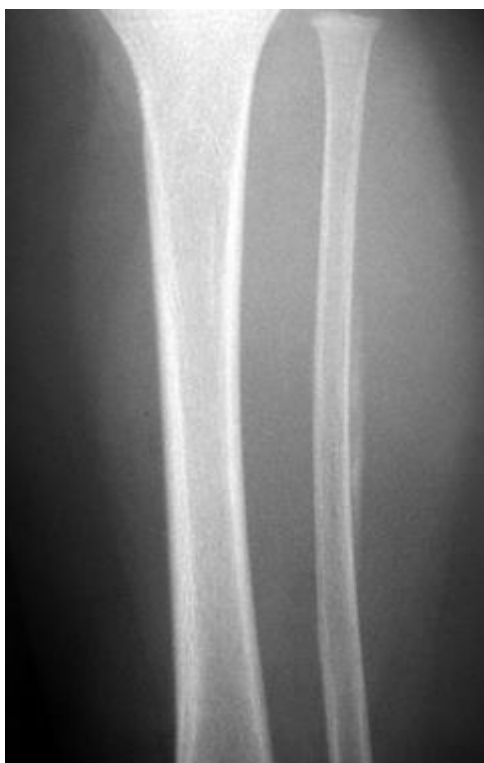

Fig. 1.a.

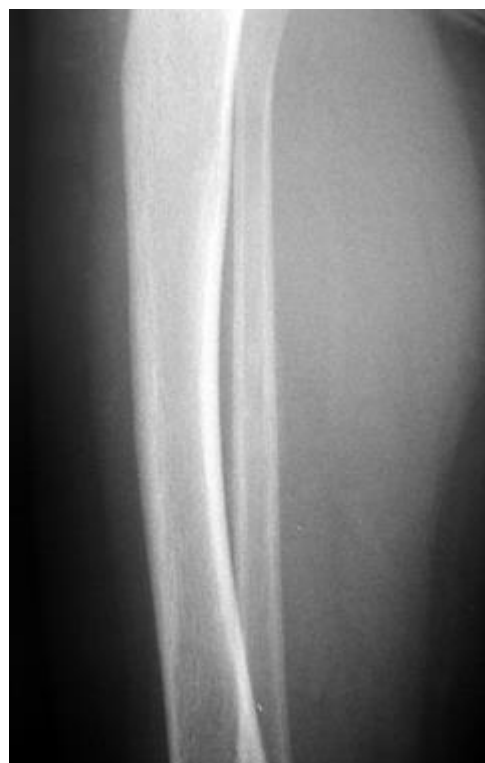

Fig. 1.b.

**Fig. 1. AP and lateral views of the left leg.**

Periosteal reaction is seen along the posterolateral margin of the fibular diaphysis. No other abnormality is visible.

Plain radiographs at the time of admission (Fig. 1(a, b)) showed periosteal reaction along the posterolateral margin of the fibula with no associated fracture. The bony cortex and medullary canal appeared normal. No soft tissue abnormality was identified.

On the basis of the clinical presentation and plain radiographic findings, it was felt that the overall clinical picture was indicative of osteomyelitis. However, a tumour such as Ewing's sarcoma could not be excluded. The patient was therefore referred to The London Bone and Soft Tissue Tumour Unit for further investigations and management.

The patient was investigated using a standard tumour protocol consisting of MRI and was booked for a CT guided needle biopsy under general anaesthesia. MRI demonstrated extensive medullary oedema throughout the fibula, a single laminated periosteal reaction and a focal area of cortical sclerosis (Fig. 2).

A CT scan was then performed to optimally visualize the bone morphology. CT showed (Fig. 3) a fracture line in the upper fibula with associated periosteal reaction. The biopsy was therefore cancelled.

#### **Discussion.**

Children under the age of 36 months have only recently started to walk and are rapidly in-

creasing their activities; a mature gait pattern is also still evolving. Trivial trauma in this background is therefore not uncommon, which results in a stress fracture of the bones of the lower limb.

In a review of 500 limping children who presented without a history of obvious trauma or abuse, Oudjhane et al found that 100 patients (20%) showed a fracture [11]. They only used plain X-rays to investigate the children. If they had used radio isotope imaging, the percentage of children showing fractures may well have been higher [12,13]. Out of the 50 children showing fractures, tibia was fractured in 51 patients. Femur was the next commonest bone to be injured (30 patients). Fibula was the third on the list with 12 cases. Out of these 7 patients had fractures of both tibia and fibula and 5 had only fracture of fibula. Various bones of the foot like calcaneus, cuboid and the metatarsals have also been described in the same clinical setting.

Donnelly [8] has described an isolated fibular fracture that was not detected on initial radiographic examination, despite the patient presenting with inability to weight bear on the left leg. A follow-up examination 2 weeks later showed periosteal reaction along the lateral shaft of the distal fibula, in a manner very similar to our patient. A case of bilateral stress fractures of the fibula secondary to walker abuse has also been described

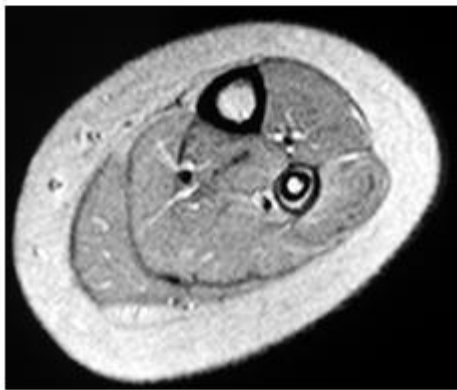
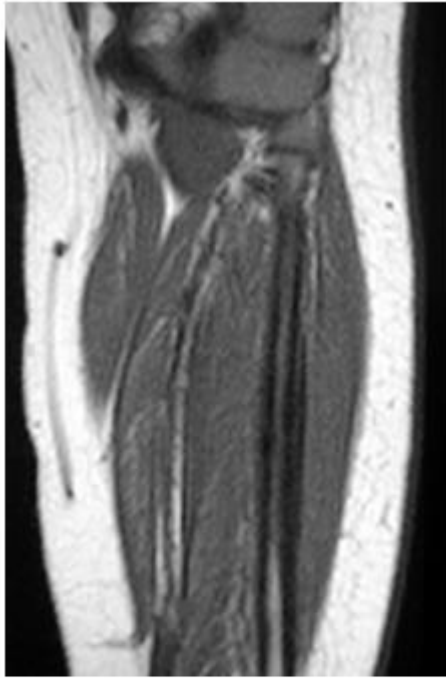


Fig. 2.a.

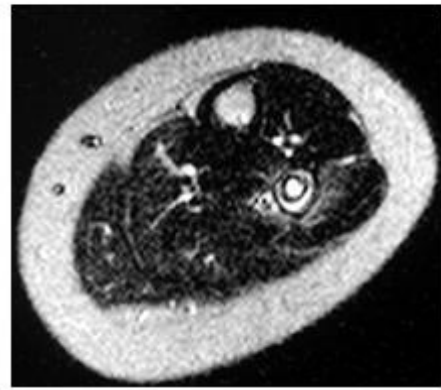
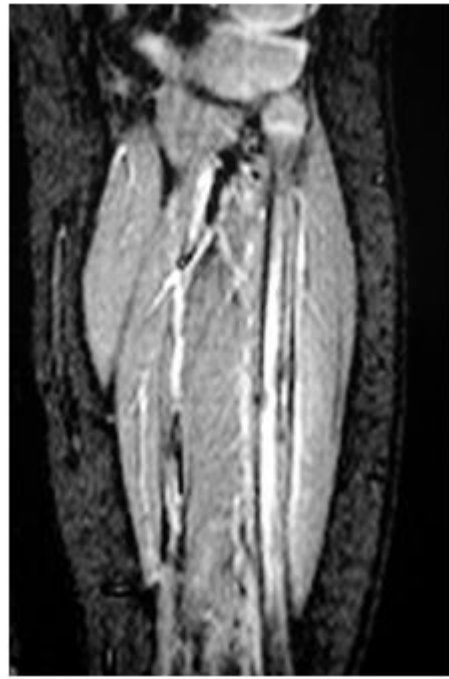
Fig. 2.b.

**Fig. 2.** MRI demonstrated extensive medullary oedema throughout the fibula, a single laminated periosteal reaction and a focal area of cortical sclerosis.

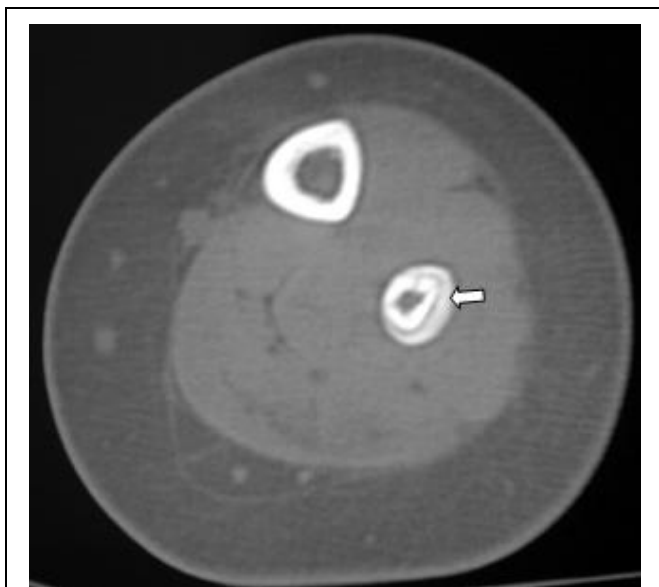
[14]. Kinnaird and Beech described three cases of fractures of fibula in toddlers who had presented with atraumatic limp [10]. The diagnosis in these cases was made on plain films and radioisotope imaging.

Stress fractures of fibula are commoner in toddlers than in adults [15]. The usual location of the injury is distal metaphyses followed by proximal metaphysis and the shaft [11]. This is in contrast to tibia where the classically described toddler's fracture is in the upper third of bone.

The child presents with a painful limp and refuses to bear weight. A history of trauma is not always available. Sleep is usually unaffected. The pain improves with rest but does not always go away until the condition is resolved. Tenderness may extend along the shaft depending on the sight of the subperiosteal reaction.

Radiographically there is a haze of internal callus along the shaft, subperiosteal new bone formation and sometimes slight disruption of the cortex. No linear fracture is radiographically evident because it is usually a compression stress fracture. The periosteum is elevated, presumably by hematoma formation, and as it calcifies, this calcification may become evident on subsequent radiograph. Sometimes the fracture is shown only by a bent in the convex margin of the bone shaft which results from axial loading resulting in plastic bowing of the bone [16,17].

Radionuclide imaging can play a role in the detection of the occult toddler's fracture. These fractures manifest as areas of increased focal uptake. The bone scan may become positive within seven hours of the injury and a negative bone scan by the third day, excludes the diagnosis of a



**Fig. 3. Axial CT slice through the upper leg, bone window, confirms the fracture demonstrated on MRI**

Florid but regular periosteal reaction is seen, with no evidence of a tumour.

fracture [18].

The differential diagnosis of this appearance on plain films and radio-isotope imaging can include conditions like osteomyelitis, eosinophilic granuloma and Ewing's sarcoma. MRI is helpful in this situation. The fracture itself both in the acute and delayed setting can be identified as a low signal intensity line. The surrounding marrow shows oedema which can be extensive. The differentiation from Ewing's sarcoma is made by the absence of a soft tissue mass and by the identification of a fracture line, as in our case. Differentiation from osteomyelitis can be tricky on radiological lines alone. The presence of a well demarcated periosteal reaction, location of the oedema focus anywhere in the bone rather than in the metaphyses typically seen in children with osteomyelitis and lack of soft tissue oedema are helpful features. The lack of systemic signs of osteomyelitis are reassuring that no infection is present.

#### Conclusion.

Awareness of the diagnosis of a toddler's stress fracture in fibula avoids an unnecessary bone biopsy. Identification of a fracture line on MR surrounded by oedema and lack of soft tissue mass clinch the diagnosis on MR.

#### References:

1. Dunbar, J. S. et al. *Obscure Tibial Fracture of Infants--the Toddler's Fracture.* *J Can Assoc Radiol*, v. 15, n. p. 136-144, 1964.
2. John, S. D.; Moorthy, C. S.; Swischuk, L. E. *Expanding the Concept of the Toddler's Fracture.* *Radiographics*, v. 17, n. 2, p. 367-376, 1997.
3. Laliotis N, Pennie BH, Carty H and Klenerman L, *Toddler's fracture of the calcaneum.* *Injury* 1993 24, (3), 169-170
4. Starshak RJ, Simons GW and Sty JR. *Occult fractures of the calcaneus-another toddler's fracture.* *Pediatr Radiol* 1984, 14: 37-40
5. Shindler Amos, Mason D, Allington N. *Occult fractures of the calcaneum in toddlers.* *J Pediatr Orthop*, 16 (2). April 1996, 201-205.)
6. Blumberg K, Patterson RJ. *The toddler's cuboid fracture.* *Radiology* 1991; 179:93-94.
7. Simonian PT, Vahey JW, Rosenbaum DM, Mosca vS, Staheli LT. *Fracture of the cuboid in children:a source of leg symptoms.* *J Bone Joint Surg [Br]* 77;1995; 104-106.
8. Donnelly, L.F. *Toddler's Fracture of the Fibula.* *AJR Am J Roentgenol*, v. 175, n. 3, p. 922, 2000.
9. Kozlowski K and Urbonaviciene A. *Stress fractures of the fibula in the first few years of life (report of six cases).* *Australas Radiol.* 1996 Aug; 40(3): 261-3
10. T P Kinnaird and R C Beach *Fractured fibula can mimic irritable hip.* *Arch Dis Child.* 2003 Feb;88(2):167
11. Oudjhane K, Newman B, Sang K, Young L and Girdany B. *Occult fractures in preschool children.* *The Journal of Trauma*; 1988; 28, 858-860.
12. De Boeck K, Van Eldere S, De Vos P, Mortelmans L, Casteels-Van Daele *Radionuclide bone imaging in toddler's fracture,* *Eur J Pediatr M Jan*;150(3):166-9.
13. Englaro EE, Gelfand MJ, Paltiel HJ. *Bone scintigraphy in preschool children with lower extremity pain of unknown origin.* *J Nucl Med.* 1992 33(3): 351-4.
14. Sheehan KM, Gordon S, Tanz R. *Bilateral fibula fractures from infant walker use* *Pediatric emergency care*, 11 (1)1995 ; 27-29
15. Devas MB. *Stress fractures in children,* *JBJS Br* 1963; 45: 528-541
16. Mabrey JD, Fitch R. *Plastic deformation in pediatric fractures: mechanism and treatment.* *J Pediatr Orthop* 1989; 9:310-314.
17. Newmann L. *Acute plastic bowing fractures of both the tibia and the fibula in a child.* *Injury* 1990; 21:122-123
18. Rosenthal L, Hill RO, Chuang S. *Observation on the use of Tc phosphate imaging in peripheral bone trauma.* 1976 *Radiology* 119: 637.